

Ozone therapy application in different ophthalmologic diseases: study of 59 cases (Aplicación de la ozonoterapia en diferentes enfermedades oftalmológicas: estudio de 59 casos)

Ivan Vigna¹, Silvia Menéndez-Cepero^{2,c}

¹Clínica Veterinaria Dr. Vigna. Vía Primo Maggio, 34 40026, Imola, Italia.
ivanvigna@tele2.it

²Clínica Internacional de Ozono, Centro de Investigaciones del Ozono, Apartado Postal 6414, Ciudad de La Habana, Cuba.

^cClínica Internacional de Ozono, Centro de Investigaciones del Ozono, Apartado Postal 6414, Ciudad de La Habana, Cuba. Tel:+537-2719264.
silviamenendez@infomed.sld.cu

RECVET: 2007, Vol. II, Nº 11

Recibido: 16.07.07 / Referencia: 110702B_RECvet / Aceptado: 15.10.07 / Publicado: 01.11.07

RECVET® Revista Electrónica de Clínica Veterinaria está editada por Veterinaria Organización®. Se autoriza la difusión y reenvío siempre que enlace con Veterinaria.org® <http://www.veterinaria.org> y con RECvet® - <http://www.veterinaria.org/revistas/recvet>

Abstract

The satisfactory use of ozone therapy in the field of Ophthalmology has been described. For the therapy of alterations in structures localized in the eye anterior segment (mainly in herpetic keratitis), in humans and Veterinary, the subconjunctival application of ozone and the use of ozonized sunflower oil (OLEOZON®) collyrium, in conjunction with ozone rectal insufflation, thanks to its immunomodulatory effect, are well known. Taking into account the OLEOZON® germicide power, its capacity to favor cicatrization and anti-inflammatory effect, the aim of this paper is to evaluate its efficacy applying it in cats affected by herpetic keratitis and chlamydiosis, as well as in corneal ulcer (herpetic or traumatic) and in corneal ulcer treated with conjunctival grafts. This study was performed in cats of different origin and age. Local treatment over the lesions was applied using OLEOZON® collyrium, every 8 hours. Evaluation was performed every 72 hours and every 4 hours in conjunctival grafts. The healing criteria were inflammation disappearance and ulcer cicatrization. In comparison with known pharmacological conventional therapies, the OLEOZON® collyrium treatment was superior, more simple and more rapid in achieving results. In one cat, where the herpetic queratoconjunctivitis induced a symblepharon, OLEOZON® accentuated it, due to its capacity to increase fibroblast expression. This can be considered as a contraindication of this medication. It is interesting to consider the good corneal cicatrization obtained with this treatment. No side effects were observed during the study.

Key words: Ozone therapy | OLEOZON® | cats | herpetic keratitis | chlamydiosis | corneal ulcer | conjunctival grafts.

Resumen

El uso satisfactorio de la ozonoterapia en la Oftalmología ha sido ya descrito. Se ha aplicado, tanto en humanos como en animales, la inyección de ozono por vía conjuntival, la insuflación de ozono rectal y el uso del colirio de aceite de girasol ozonizado (OLEOZON®) para la terapia de alteraciones de estructuras localizadas en el segmento anterior del ojo (sobretudo en la queratitis herpética). Teniendo en cuenta el carácter germicida del OLEOZON®, su capacidad de favorecer la cicatrización y su efecto anti-inflamatorio, el objetivo de este trabajo es evaluar su eficacia en gatos afectados de queratitis herpética y clamidiosis, así como en úlceras corneales (herpéticas o traumáticas) y en úlceras corneales tratadas con trasplantes conjuntivales. Este estudio se realizó en gatos de diferente origen y edad. Se aplicó colirio de OLEOZON®, cada 8 horas, como tratamiento local sobre las lesiones. La evaluación se realizó cada 72 horas y en el caso de los trasplantes conjuntivales cada 4 horas. El criterio de curación fue la desaparición de la inflamación y la cicatrización de la úlcera. En comparación con las terapias farmacológicas convencionales conocidas, el tratamiento con el colirio de OLEOZON® fue superior, siendo más simple y más rápido en alcanzar los resultados. En un gato, donde la queratoconjuntivitis herpética indujo un simblefaron, el OLEOZON® lo acentuó, debido a su capacidad de incrementar la expresión de fibroblastos. Esto puede considerarse como una contraindicación de este medicamento. Es interesante considerar la buena cicatrización corneal obtenida con este tratamiento. No se observaron reacciones adversas durante el estudio.

Palabras claves: Ozonoterapia | OLEOZON® | gatos | queratitis herpética | clamidiosis | úlcera corneal | trasplantes conjuntivales.

Introduction

Ozone therapy in Ophthalmology has been studied mainly in Cuba, where retinitis pigmentosa, glaucoma, age-related degenerative retinal maculopathy, keratoconjunctivitis and corneal ulcer in human medicine have been treated in a particular way.¹⁻¹⁵

In the front zone of the eye there are structures that need vascularization and rapid cicatrization in the case of disease, besides antibacterial and antiviral action is required. Theoretically in this case, ozone therapy can be indicated considering that these pathologies are difficult and take a long time to be treated by conventional therapies.

Some interesting works were made in Japan¹⁶ about the use of ozonized solutions in pre-surgical disinfection and in Poland,¹⁷ about the utilization of an ozonized collyrium in virus conjunctivitis and corneal degeneration after inflammatory conditions and chemical burns.

OLEOZON® is obtained from the reaction between ozone and sunflower oil in appropriate conditions, obtaining aldehydes, carboxylic acids, together with hydroperoxides, ozonides and other peroxides species.¹⁸ It has been already registered in Cuba for the treatment of tinea pedis, impetigo and giardiasis. This product presents a remarkable germicidal nature. It has been verified, *in vitro* and *in vivo*, its antimicrobial effects against virus, bacteria and fungi^{19,20} and also, in the

treatment of infections produced by multi-resistant strains.²¹ On the other hand, toxicological studies have demonstrated that this product is not mutagenic or genotoxic and has not side effects in the treated patients.²²⁻²⁵

Taking into account the OLEOZON® great germicide power, the capacity to favor cicatrization and anti-inflammatory effect, the aim of this paper is to evaluate its efficacy in cats affected by herpetic keratitis and *Chlamidiophila Felis* conjunctivitis, as well as in deep corneal ulcer and in corneal ulcer treated with conjunctival grafts.

Materials and methods

This study was carried out in 59 cats with different problems in the eye's front area. Most of the cats lived in cats refuge of Imola (32 cats) the others were brought from owners in our clinic for an ophthalmological visit.

A high efficient ophthalmoscope for the direct ophthalmoscopy, slit lamp, Schiøtz tonometer, Schirmer test, sodium fluorescein 2%, Bengala pink and an indirect binocular ophthalmoscope for the indirect ophthalmoscopy were use for the ophthalmologic evaluation.

Diseases treated were.²⁶⁻³¹

- Herpetic keratoconjunctivitis (24 cases)
- Conjunctivitis due to *Chlamidiophila Felis* (17 cases)
- Mixed keratoconjunctivitis due to herpes virus, *Chlamidiophila Felis* and mycoplasma (7 cases)
- Deep corneal ulcer of different causes (herpetic and traumatic) (7 cases)
- Corneal ulcer of various causes treated with ozonized conjunctival graft (4 cases)

All the cases have been treated with OLEOZON® collyrium. In corneal ulcer, also a mydriatic (Tropicamide 0.12%) has been used three times per day to avoid synechias. Follow-up has been made every 4 hours after the conjunctival graft surgery, every 24 hours in corneal ulcers and every 72 hours in other cases.

Results have been compared with those coming from traditional therapy.

Results and discussion

Results and discussion

• HERPETIC KERATOCONJUNCTIVITIS

Totally 24 cats, 15 cats were guests in the communal cats refuge. Diagnosis was made watching clinical symptoms with Bengala pink coloration and in the uncertainty cases using PCR on conjunctival material.

Symptomatology: 9 cats presented only simple keratitis or superficial ulcer; 15 cats presented the acclaimed form of herpetic rhinotracheitis with inflammation symptoms

of first aerial ways and keratoconjunctivitis, rhinitis and tracheitis. In these 15 cases aerosol therapy was made using physiological solution.

Traditional therapy foresees the use of antiviral and antibiotic collyrium and pomade, antibiotic systemic therapy and aerosol therapy.³²⁻³⁵

Usually, improvement is very slow, moreover perforated corneal ulcers are frequent and recidivations are extremely frequent.

In our study, OLEOZON® collyrium therapy administrated by a posology of two drops every eye three times a day, has allowed rapid improvement, in 5-6 days, no cases of perforated corneal ulcer and a very low percentage of recidivations (8 %), limited only to the reappearance of subacute rhinoconjunctivitis in two kittens.

Only in one case OLEOZON® collyrium resulted as contraindicated: when herpes had induced a symblefaron. We think that this behaviour is related to the properties of ozonized oil that stimulates fibroblasts and therefore accents the symblefaron.

• **CHLAMIDIOPHILA FELIS CONJUNCTIVITIS**

Totally 17 cases, 13 were kittens living in the cat refuge nursery, the other 4 were sent to our clinic by colleagues for specialized visits.

Chlamidiophila felis is an obliged intracellular bacterium which can infect man. It is one of the most important pathogenic agents in cats. It is responsible of a severe acute conjunctivitis associated with chemosis, photophobia and ocular secretion. Kittens aged from 5 to 9 weeks are more affected and it is never associated with keratitis. Diagnosis is made through PCR or immunofluorescence on the conjunctival curettage.³³⁻³⁶

In the severe cases, as the ones we discovered, therapy consists on topical tetracycline every 8 hours for at least 2 weeks; diagnosis was made by PCR.³³⁻³⁶

These kittens instead were treated with OLEOZON® collyrium, two drops in the conjunctivae fornix, every 8 hours. The 4 kittens brought to our clinic for ophthalmologic visit had already been previously treated with chloramphenicol-tetracycline association without any improvement, on the contrary the situation worsened.

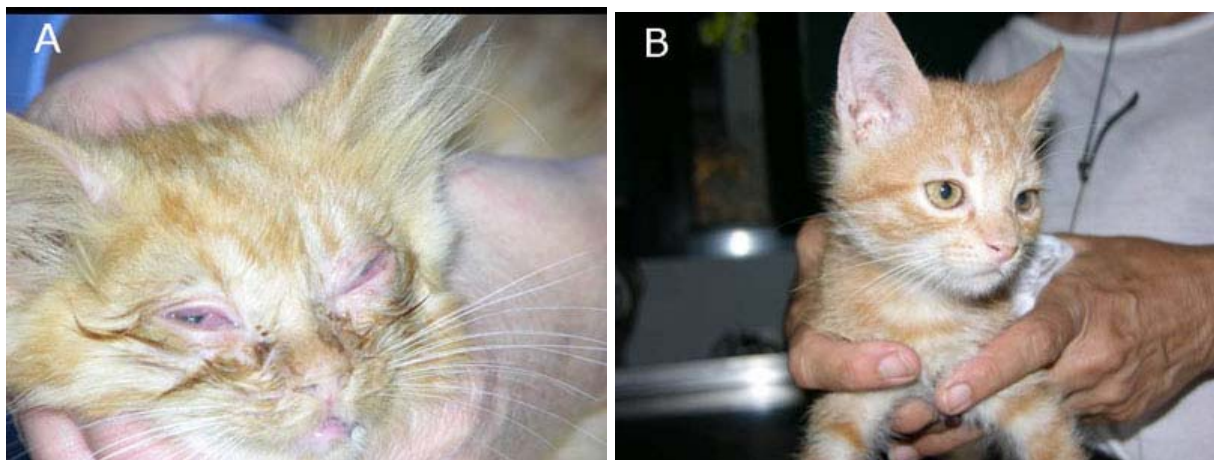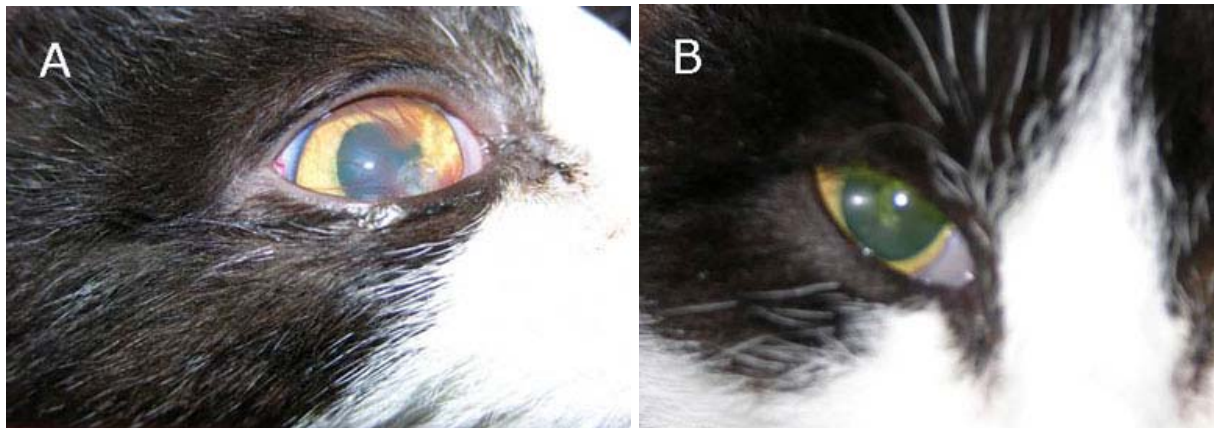
After only 3 days of treatment all the kittens, including the ones refractory to antibiotics, showed a great improvement and after 10 days of therapy all the cats were completely healed. No relapses occurred.

• **MIXED KERATOCONJUNCTIVITIS (HERPERVIRUS + CHLAMYDIA + MYCOPLASMA)**

In 7 kittens treated for a keratoconjunctivitis was found the contemporary presence of:

1. Herpes virus
2. *Chlamidiophila felis*
3. Mycoplasma

The observed symptomatology was similar to a rhinoconjunctivitis with severe chemosis, ocular secretion and corneal ulcer.³³⁻³⁶ Therapy consists of OLEOZON® collyrium, two drops every 8 hours, besides Tropicamide 0.12% (one drop twice a day) to avoid probable synechias. After 6 days of therapy, edema disappeared and after 15 days the complete resolution of symptoms was registered with healing of the herpetic corneal ulcers. Figures 1 and 2 are examples of the evolution of an herpetic corneal ulcer and a severe acute conjunctivitis due to the bacterium *Chlamidiophila felis*, respectively, after the treatment with OLEOZON® collyrium.

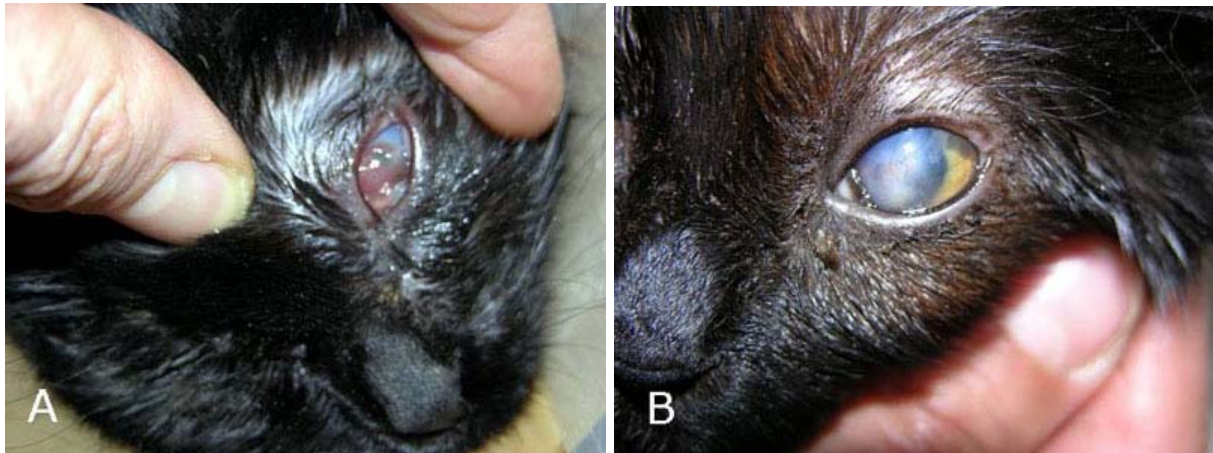


- **DEEP CORNEAL ULCERS (DEEP STROMAL ULCERS), DESCEMETOCELE, PERFORATED ULCERS.**

Deep corneal ulcers are known as the stromal ones with dimensions superior to 1/3 of the corneal thickness.^{33,37-39} Usually they should be treated with surgery, therefore, for hectic reasons we used OLEOZON® collyrium, but only in cases in which surgery was not authorized by the owners; totally 7 cases.

Maybe these are the most interesting cases because, completely experimental, they permitted us to test the possibilities of the use of ozonized oil in Ophthalmology. We treated 2 perforated ulcers, 1 descemetocele and 4 deep ulcers. Therapy consisted

of OLEOZON® collyrium, three drops every 6 hours, and Tropicamide 0.12%, one drop every 8 hours. We obtained healing in 6 cases; in one (a perforate ulcer) cornea cicatrized, but we couldn't avoid front synechias. Complete healing was obtained for the deep ulcers in 7-9 days, for descemetocoele in 7 days, while for the perforated ulcers after 10 days cornea cicatrized and in 30 days looked perfectly transparent (see figure 3).

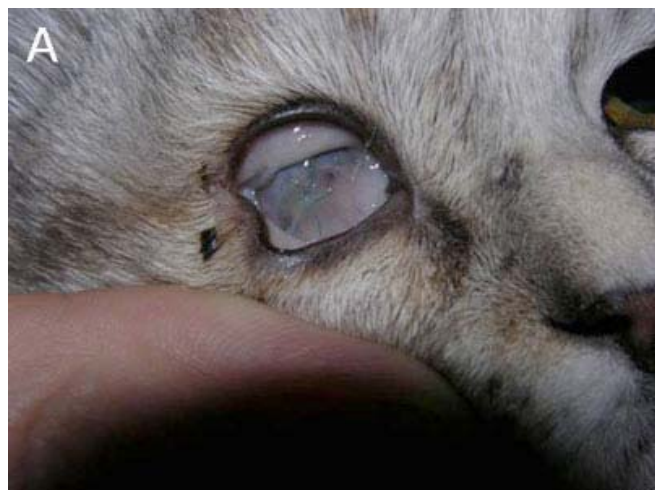

- **FREE AND PEDUNCULATE CONJUNCTIVAL GRAFTS TREATED WITH OZONIZED OIL**

As a rule, when we must treat a deep ulcer we choose surgery, utilizing simple sutures with peduncular conjunctival grafts or using generally autologous tissue grafts. Conjunctival grafts can be free or pedunculate, as a bridge. Sometimes the corneal tissue loss is so important that it results very difficult to make peduncular grafts, so only a free graft can be made.³⁸⁻⁴¹

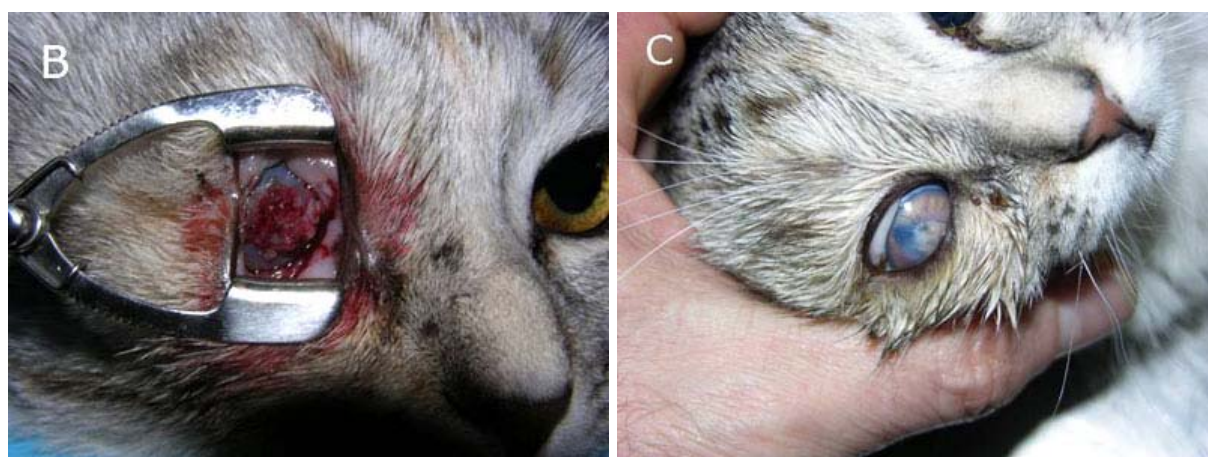The main problem about free grafts is the lack of vascularization, so we thought to treat these eyes with ozonized oil in order to stimulate the creation of new vascularization and opposing bacterium responsible of collagenolisis.

We treated in this way a cat presenting crystalline lens luxation in anterior chamber; the lens was subsequently ejected causing an enormous corneal tissue loss. Some colleagues suggested enucleation, but we attempted to save the eye through a surgical free graft immediately treated with ozonized oil. We treated the graft 6 times per day with three drops of OLEOZON® collyrium and Tropicamide 0.12%, one drop every 8 hours. After 48 hours the graft got vascularization and treating the part 3 times per day with three drops of OLEOZON® collyrium, the cornea turned transparent and the eye



was conserved.

In 3 cats with very large collagenolytic perforated ulcer (one of them presenting lens luxation and ejection) we tried to apply the pedunculated graft treating the part 3 times per day with three drops of ozonized oil. After 4 days we cut the peduncle, continuing the therapy with OLEOZON® collyrium three drops four times a day on the free graft. This free graft got vascularization in 2 days and in 10 days we obtained a corneal integrity (see figure 4).



Conclusions

In almost all the cases the results have been satisfactory. In both cases in which we needed an antibacterial and antiviral effect and in the ones where we needed a fast cicatrization and vascularization the results with OLEOZON® collyrium satisfied the expectations.

Also, it must be considered the utility of this medical technique that foresees only a limited number of daily administrations, each determined hours, to obtain its good results.

This therapy is also cheap, mainly if we consider the price of the antiviral collyrium, which at the end did not show advantages as regards to OLEOZON® collyrium.

No side effects were observed during the study and the collyrium was well accepted by animals.

Bibliography

1. Copello M, Eguía F, Menéndez S, Menéndez N. Ozone therapy in patients with Retinitis Pigmentosa. *Ozone-Sci Eng* 2003;25(3):223-32.
2. Menéndez S, Peláez O, Gómez M, Copello M et al. Aplicación de la ozonoterapia en la retinosis pigmentaria. *Rev Cubana Oftalmol* 1990;3(1):35-9.
3. Marmer R and Parks S. Ozone treatment in retinitis pigmentosa: effect on color perception and blood gasses. *Ann Ophthalmol* 1998;30(3):161-3.

4. Marmer R and Parks S. Ozone treatment in retinitis pigmentosa: effect on photo stress and contrast sensitivity. *Ann Ophthalmol* 1998;30(3):164-6.
5. Ferrer L, Santos D, Menéndez S y Pérez Z. Ozonoterapia y magnetoterapia: nuevos métodos en la rehabilitación del paciente con glaucoma crónico simple. *Rev Cubana Oftalmol* 1996;9(2):102-9.
6. Ibáñez M, Rodríguez A, Ferrer L y Fernández G. Estudio comparativo de dos métodos terapéuticos en el glaucoma crónico simple. *Rev Cubana Oftalmol* 1996;9(2):110-5.
7. Ferrer L, Varela F y Fernández I. Mecanismo de acción local de la ozonoterapia y su combinación con el campo magnético en pacientes con glaucoma primario de ángulo abierto estadio inicial. *Rev Cubana Oftalmol* 2004;17(2):1-5.
8. Bocci V. Oxygen-Ozone Therapy. A critical evaluation. Dordrecht, The Netherlands: Kluwer Academic Publishers, 2002;243-341.
9. Riva Sanseverino E., Meduri R.A., Pizzini A. *et al.* Effects of oxygen-ozone therapy on age-related degenerative retinal maculopathy. *Panminerva Med* 1990;32:77-84.
10. Diadori A, Bocci V, Carraro F, Nuti A, Corradeschi F, Ferrari G, Sabatini L, Silvestri S and Frezzotti R. Ozonotherapy and age-related macular degeneration: a pilot study. In F. Ceccherelli and F. Giron, eds. *L'Ozonoterapia nel 2000*. Torino: Edizioni Libreria Cortina, 1999:33-45.
11. Diadori A, Nuti A, Ferrari G, Corradeschi F and Bocci V. Ozone therapy: a new perspective in ophthalmology. *Vision Res* 1996;36(suppl.):418.
12. Perone G., Incarbone F., Schmidt M., Franzini M. Case report: oxygen-ozone therapy in pigmentary epithelium detachment. *Annali di Ottalmologia e Clinica Oculistica* 1996;CXXII (N. 11):593-7.
13. Incarbone F, Perone G, Franzini M, Bertè F, Schmidt M. *Atti del Congresso New Developments in the Treatment of Age Related Macular Disease*. Gardone Riviera, 22-24 Giugno 1997.
14. Viebahn R. Die Senile Makulopathie und Verwandre Erkrankungen. In: E.G. Beck and R. Viebahn-Hänsler, eds. *Ozon-Handbuch. Grundlagen. Prävention. Therapie*. Landsberg, Germany: Ecomed, 1999:1-25.
15. Piña JC, Mapolón Y, Palma M, Recio E, Harrys C, Rodríguez M. Application of ozone in Patients with Keratitis. 4th International Symposium on Ozone Applications. Cuba, March 1997.
16. Kashiwagi K, Saito K, Wang YD, Takahashi H, Ishijima K, Tsukahara S. Safety of ozonated solution as an antiseptic of the ocular surface prior to ophthalmic surgery. *Ophthalmologica* 2001 Sep-Oct;215(5):351-6.
17. Gierek-Lapinska A, Antoszewski Z, Myga B Skowron J. Preliminary report on using therapeutic ozone in infectious conjunctivitis and keratitis and in corneal degeneration. *Klin Oczna* 1992 May-Jun;94:5-6.
18. Díaz M, Hernández F, Alvarez I, Velez I, Ledea O. 1-H-NMR studies of the ozonation of methyl oleate. *Boletín de la Sociedad Chilena de Química* 1997;42:349-353.
19. Lezcano I, Nuñez N, Molerio J, Gómez M. Actividad in vitro del aceite de girasol ozonizado frente a diferentes especies microbianas. *Revista CENIC Ciencias Biológicas* 1996;27(1-3):46 - 50.
20. Lezcano I, Molerio J, Gómez M, Contreras R, Roura G, Díaz W. Actividad in vitro del OLEOZON® frente a agentes etiológicos de infecciones en la piel. *Revista CENIC Ciencias Biológicas* 1998;28(1-3):105-109.
21. Lezcano I, Nuñez N, Espino M, Gómez M. Antibacterial activity of ozonized

- sunflower oil, OLEOZON®, against staphylococcus aureus and staphylococcus epidermitis. *Ozone-Sci Eng* 2000;22(2):207-214.
22. Llerena C, García G, Molerio J, Menéndez S. Irritabilidad dérmica del OLEOZON®. *Revista CENIC Ciencias Biológicas* 1995;26:104-109.
 23. Martínez G, León OS. Toxicidad aguda dérmica del OLEOZON® en ratas y conejos. *Revista CENIC Ciencias Biológicas* 1995;26:100-104.
 24. Remigia A, González Y, Zamora Z, Molerio J. Evaluación genotóxica del OLEOZON®. *Revista CENIC Ciencias Biológicas* 1998;28(1-3):65 - 70.
 25. Díaz M, García G, García K, Sánchez Y, Tillán J. Evaluación de la irritabilidad dérmica, oftálmica y el efecto sensibilizante del OLEOZON® tópico. *Revista Electrónica de Veterinaria REDVET nov 2006;VII(No.11)*. Disponible en URL:<http://www.veterinaria.org/revistas/redvet/n111106.html>.
 26. Andrew SE. Ocular manifestations of feline herpesvirus. *J Feline Med Surg* 2001;3:9-16.
 27. Andrew SE, Tou S, Brooks DE. Corneoconjunctival transposition for the treatment of feline corneal sequestra (1990-1998). *Vet Ophthalmology* 2001;4:107-11.
 28. Featherstone HJ, Sansom J. Intestinal submucosa repair in two cases of feline ulcerative keratitis. *Vet Rec* 2000;146:136-8.
 29. Rampazzo A, Appino S, Pregel P. Prevalence of chlamydia felis and feline herpesvirus 1 in cats with conjunctivitis in northern Italy. *J Vet Intern Med* 2003;17:799-807.
 30. Ramsey DT. Feline Chlamydia and calicivirus infections. *Vet Clin N Am-Small Anim Pract* 2000;30:1015-28.
 31. Cole BC, Golightly L, Ward JR: Characterization of Mycoplasma strain from cats. *J Bacteriol* 1967;94:1451-8.
 32. Williams DL, Fitzmaurice T, Lay L. Efficacy of antiviral agents in feline herpetic keratitis: results of an in vitro study. *Curr Eye Res* 2004;29:215-8.
 33. A.Guandalini, C.Peruccio, S.Pizzirani. *Oftalmologia*. Italia:Poletto Editore, 2006.
 34. Dice P. Cornea. In: Gelatt KN, eds. *Veterinary Ophthalmology*. Philadelphia, USA: Lea & Febiger eds, 1981:370.
 35. Gelatt KN. *Veterinary ophthalmology*. III Ed. Philadelphia:Lipincott Williams & Wilkins eds,1999.
 36. Barnett KC, Crispin SM. *Feline ophthalmology: an atlas and text*. London:Saunders, 1998.
 37. Fini ME, Cook JR, Mohan R. Proteolytic mechanism in corneal ulceration and repair. *Arch Dermatol Res* 1998;290 Suppl:S12-23.
 38. La Croix NC, Van Der Woerd A, Oliviero DK. Nonhealing corneal ulcers in cats: 29 cases (1991-1999). *J Am Vet Med Assoc* 2001;218:733-5.
 39. Morgan RV, Abrams KL. A comparison of six different therapies for persistent corneal erosions in dogs and cats. *Veterinary & Comparative Ophthalmology* 1994;4:38-43.
 40. Gelatt KN, Gelatt JP. *Small animal ophthalmic surgery*. Edinbourg: Butterworth-Heinemann, 2001.
 41. Bussieres M, Krohne SG, Stiles J, Townsend WM. The use of porcine small intestinal submucosa for the repair of full-thickness corneal defects in dogs, cats and horse. *Vet Ophthalmology* 2004;7:352-9.